

# Clinical review: Vascular access for fluid infusion in children

- Nikolaus A Haas

Critical Care 2004;8:478

<https://doi.org/10.1186/cc2880>

© BioMed Central Ltd 2004

- **Published:** 3 June 2004

## Abstract

The current literature on venous access in infants and children for acute intravascular access in the routine situation and in emergency or intensive care settings is reviewed. The various techniques for facilitating venous cannulation, such as application of local warmth, transillumination techniques and epidermal nitroglycerine, are described. Preferred sites for central venous access in infants and children are the external and internal jugular veins, the subclavian and axillary veins, and the femoral vein. The femoral venous cannulation appears to be the most safe and reliable technique in children of all ages, with a high success and low complication rates. Evidence from the reviewed literature strongly supports the use of real-time ultrasound techniques for venous cannulation in infants and children. Additionally, in emergency situations the intraosseous access has almost completely replaced saphenous cutdown procedures in children and has decreased the need for immediate central venous access.

## Keywords

- central venous access
- child
- epidermal nitroglycerine
- intraosseous
- transillumination
- venous cutdown

## Introduction

Nothing can be more difficult, time consuming and frustrating than obtaining vascular access in the paediatric patient. This was best described by Orłowski in 1984 [1], who stated, 'My kingdom for an intravenous line'. This article reviews the various sites and techniques that may be used to gain acute intravascular access in the routine situation and in emergency or intensive care settings.

## Methods

A Medline search (publication dates up to 13 December 2003) was performed using the following MeSH terms: local warmth, epidermal nitroglycerine, GTN, transillumination, peripheral venous access, infant, child, newborn, intraosseous, central venous access, internal jugular vein, subclavian vein, axillary vein, external jugular vein, femoral vein, venous cutdown and complication, and success. Additionally, references from the primary literature were screened and previous reviews, including cross-references and conference and symposia proceedings, were used. Other sources included the Cochrane Central Register of Controlled Trials. From more than 400 references retrieved, the randomized trials and most recent and important articles were used in the present review.

## **Facilitating techniques for peripheral venipuncture**

The application of a tourniquet, tapping or stroking of visible veins, vigorous swabbing, clenching the hand to pump up veins, and hanging the forearm downward help to produce local venous dilatation and increase the visibility and palpability of the veins. To increase the success rate of venipuncture in children, the following other techniques have been used.

### **Local warming**

Local warming dilates the arterioles and decreases  $\alpha_2$ -adrenergic vasoconstriction. The hand or lower arm can be warmed by wrapping it in towels moistened with warm/hot water or immersing it in warm water. Only one randomized controlled trial assessed the effect of this procedure in facilitating insertion of venous cannulae. In adult patients, Lenhard and coworkers [2] showed that local warming facilitates the insertion of venous cannulae, and reduces the time and number of attempts required. A controlled study conducted in children is not available.

### **Transillumination techniques**

Finding an accessible vein in infants is frequently difficult when the skin is coloured, the infant is dehydrated, obese or shocked, or when the commonly accessible veins are exhausted. Transillumination techniques have been used for many years to facilitate arterial puncture [3] and venous access [4]. Various devices for transillumination have been described but have not gained popularity. Commonly used are cold-light fiberoptic techniques; complications (burns) are rare but possible [5, 6]. A 40% efficacy of palm transillumination using a common otoscope in an emergency department setting was recently reported [7], and venous access could be established in 39 out of 40 patients with just one venipuncture.

### **Epidermal nitroglycerine**

Ointments containing nitroglycerine (GTN) have been used to produce local dermal vasodilatation. The first successful use of GTN ointment as an aid to venipuncture was reported in 1983 in a randomized placebo-controlled trial [8]. Other investigations showed an increasing diameter of the veins [9, 10], or better success rate for venipuncture [11].

The local application of GTN was efficient in reducing venipuncture failure in children younger than 1 year [12]. However, these results could not be reproduced in another series [13]. Adverse local and systemic side effects were found in neonates and premature babies, and therefore the use of GTN cannot be recommended in this age group [14].

The combination of GTN with local anaesthetics (EMLA – eutectic mixture of local anaesthetics) had a beneficial effect in adults by increasing the ease of venipuncture and decreasing the pain and the dose of local anaesthetic required. These results were confirmed in a double-blind randomized controlled trial in 104 children aged between 1 and 11 years [15]. The addition of topical GTN positively affected venous dilatation ( $P < 0.01$ ), choice of cannulation site ( $P < 0.001$ ) and ease of cannulation ( $P < 0.001$ ). Similar findings were achieved when GTN was applied after EMLA removal [16].

## Central venous access

The cannulation of a central vein allows administration of large volumes of fluids in short times and at high osmolarities for rehydration, volume replacement, chemotherapy and parenteral nutrition. In addition, it enables haemodynamic monitoring and rapid administration of drugs during cardiopulmonary resuscitation. Percutaneous central venous line insertion has replaced peripheral venous cutdown as the primary mode of short-term venous access in children [17, 18]. The central venous catheter (CVC) can be inserted into the femoral, jugular and subclavian veins or other influent veins, and in most cases catheter insertion is feasible and safe in all age groups [19, 20]. A summary of the features of the different infusion sites is presented in Table 1.

Table 1

Features of the different sites for intravenous access for fluid infusion in children

	<b>IO access</b>	<b>Subclavian vein</b>	<b>Femoral vein</b>	<b>Internal jugular vein</b>	<b>External jugular vein</b>	<b>Axillary vein</b>	<b>Venous cutdown</b>
Emergency access	++++	++	+++	++	+++	+	++
Ease of access for unexperienced clinician	++++	++	+++	++	+++	+	+
Infection	+	++	++	++	+	+	++
Thrombosis	0	+	++	+	+	+	++++
Other complications	+	++	+	+	0	+	0
Long-term use	0	+++	++	++	+	+	0
Short-term use	++++	++	+++	+++	++	+++	++
References	[89, 90, 91, 92, 93, 94, 95, 96, 97, 98, 99, 100, 101, 102, 103, 104, 105, 106,	[37, 38, 39, 40, 41, 42, 43, 44, 45, 46, 47, 48]	[21, 22, 23, 24, 25, 26, 27, 28, 29, 30, 31, 32, 33, 34, 35, 36]	[49, 50, 51, 52, 53, 54, 55, 56, 57, 58, 59, 60, 61, 62, 63, 64, 65, 66, 67, 68]	[78, 79, 80, 81, 82, 83]	[69, 70, 71, 72, 73, 74, 75, 76, 77]	[111, 112, 113]

	<b>IO access</b>	<b>Subclavian vein</b>	<b>Femoral vein</b>	<b>Internal jugular vein</b>	<b>External jugular vein</b>	<b>Axillary vein</b>	<b>Venous cutdown</b>
	<a href="#">107</a> , <a href="#">108</a> , <a href="#">109</a> , <a href="#">110</a> , <a href="#">116</a>						

IO, intraosseous; 0, no effect/not suitable/no risk; +++, excellent effect/very suitable/high risk

## **Femoral vein**

The standard procedure for puncturing the femoral vein has a high success rate and a low rate of arterial puncture in paediatric emergency treatment and in the intensive care unit setting [[17](#), [21](#)], even with unexperienced operators [[22](#)]. It was successful in about 92% in critically ill patients [[23](#)], in about 89–95% in children, and in about 80% in preterm infants weighing less than 1000 g [[24](#), [25](#), [26](#)]. A higher success rate can be achieved in obese children using ultrasound techniques [[27](#)].

Femoral venous catheterization is a safe method [[17](#), [28](#)] because it does not expose the patient to the potential hazard of intrathoracic complications [[29](#)]. Stenzel and colleagues [[30](#)] demonstrated a 3.7% complication rate for femoral CVC as compared with 7.3% for nonfemoral CVCs. Goldstein reported a catheter-related sepsis rate of 4.9% and mechanical complications of 3.5% in burned children [[31](#)]. The rate of femoral vein thrombosis varies from 4% to 35%, and this is adversely influenced by age, size and underlying condition of the patient [[32](#), [33](#), [34](#)]. Heparin-bonded material may significantly reduce femoral catheter-related thrombosis and infection [[35](#)]. Cannulating the femoral vein is difficult in more than 50% of patients after previous cardiac catheterization, and therefore the contralateral side should be used in the first attempt in such patients [[36](#)].

## **Subclavian vein**

Subclavian vein catheterization has proved to be a rapid alternative to surgical cutdown techniques for venous access in children [[20](#), [37](#), [38](#), [39](#), [40](#)]. However, the overall reported complication rate varies significantly from about 3% to 34%, depending on age, indication and side of puncture [[19](#), [29](#), [40](#)].

Finck and coworkers [[41](#)] reported that subclavian access was successful in 78.8% of patients younger than 6 months (average weight 3.1 kg) and in 96% of those older than 6 months (average weight 7.6 kg); there were no complications. Citak and colleagues [[42](#)] found similar results in 148 out of 156 central venous attempts (94.9%) in which subclavian vein catheterization was chosen, with a moderate complication rate (arterial injury 12.8% and pneumothorax in two patients; no mortality occurred) and a high success rate 'in experienced hands'.

However, in a large (2290 central venous catheterizations) prospective multicentre study, Iovino and coworkers [[43](#)] demonstrated that the overall risk for complications with subclavian puncture was significantly elevated when compared with internal jugular puncture

[42]. The main complications were pneumothorax and arterial puncture, but a low rate of thrombosis was noted.

Various ultrasound techniques and atrial ECG guidance have been used in an attempt to improve success rates [44, 45, 46].

The puncture technique and position of the patient are different in children compared with adults. Positioning without a shoulder roll and placing the head in a neutral position (Fig. 1) optimizes vein diameter [47]. Jung and coworkers [48] showed that tilting the head toward the catheterization side after successful puncture reduced the incidence of catheter malposition.

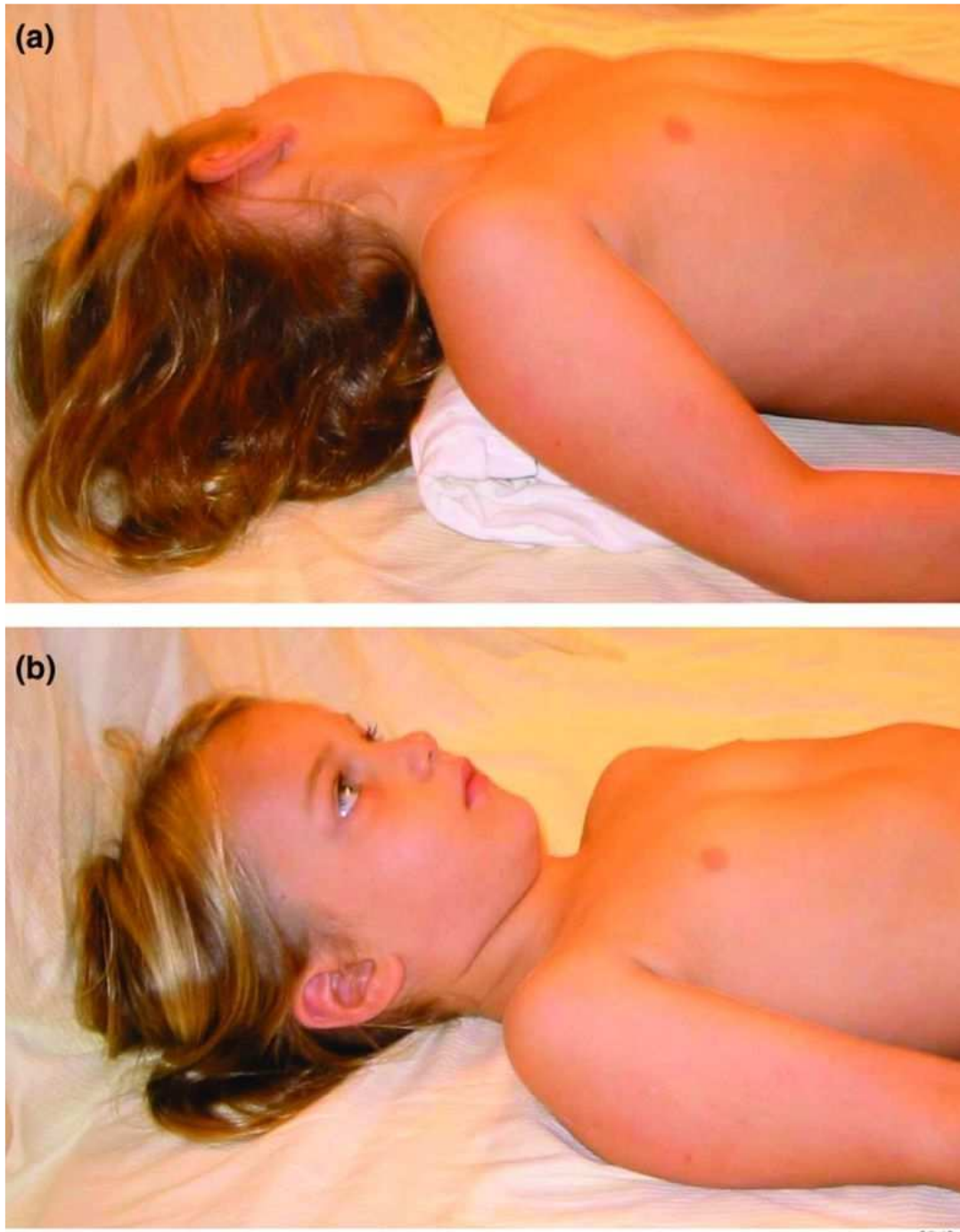


Figure 1

The puncture technique for subclavian catheterization is different in children than in adults. (a) The traditional positioning, with a shoulder roll and tilting of the head in the opposite direction. (b) Optimal positioning, enhancing the subclavian vein diameter [47].

## **Internal jugular vein**

The internal jugular vein (IJV) provides a useful and reliable site with a low failure rate, and its cannulation is traditionally performed with the aid of both palpation and anatomical landmarks. Various approaches may be used to reach the IJV [49]. Variations between the carotid artery and the IJV, and the depth and size of the IJV may account for failure to locate the vein [50, 51, 52], and these factors were found to be independent of age and size [53]. The IJV was found directly anterior to the carotid artery, at the level between the two heads of the sternocleidomastoid muscle, in about 50% of cases, and anterior or anterolateral at the level of the cricoid cartilage in about 30% of the cases [54, 55].

Doppler ultrasound guided puncture could reduce the time and the number of attempts for successful cannulation [56, 57, 58]. Direct two-dimensional ultrasound identification proved to be more precise and efficient [45, 59], especially in small children, and it is now recommended when difficulties are anticipated, complications have been encountered, or when repeated IJV cannulation is required [60, 61].

Vergheze and colleagues [62] reported a 100% success rate using ultrasound guided IJV cannulation in infants, as compared with a 75% success rate using a traditional palpation method, and the incidence of carotid artery punctures was 0% versus 25%. In 2002, these findings were repeated by Asheim and coworkers [63], who found a 100% success rate in 45 consecutive children and a median time to aspirate blood from the IJV of 12 s. Complications include arterial puncture, haematoma formation and catheter malposition, but thrombosis and pneumothorax are rarely reported.

The diameter of the IJV may vary significantly during respiration and after various manoeuvres to increase intravascular filling and pressure [64, 65], and the Valsalva manoeuvre, the Trendelenburg position and manual compression of the liver increased the size of the IVC [66, 67, 68].

## **Axillary vein**

Percutaneous catheterization techniques for the axillary vein have been described since 1967 for adults, children and neonates [69, 70]. Successful and safe use was demonstrated during resuscitation [71], and the risk for catheter-related infections or thrombosis is similar to that with other CVC sites [72, 73].

In neonates, axillary vein cannulation was found to be successful in 217 out of 226 patients, with infection occurring in three and shoulder oedema occurring in eight of the 217. Possible but rare other complications are pleural effusion, haematoma and pneumothorax [74, 75, 76].

In children the axillary approach was found to be an acceptable route for central venous catheterization in about 80%, and the risk of complications was 1.1% per catheter-day [76]. Again, the overall success rate can be improved significantly by ultrasound-guided cannulation [77].

## External Jugular vein

Use of the external jugular vein (EJV) for central venous access with a guide-wire technique is associated with a 75–100% success rate in adult patients and a very low complication rate [78].

Applicability in children was first demonstrated by Humphrey and Blitt in 1982 [79]. The overall success rate reported is lower than that in adults, ranging from 54% to about 92%. When the EJV was visible, there were no serious complications reported [80, 81, 82]. A large series of EJV cannulations was reported by Soong and coworkers [83] in 1995. That group used the EJV in 488 out of 1318 central venous accesses in a paediatric/neonatal intensive care unit. The initial success rate was high (>90%); however, the EJV catheters were used for a shorter period of time.

## Intraosseous infusions

Over the past two decades, the intraosseous (IO) route into the tibia has become a widely accepted procedure for the resuscitation of critically ill and injured children [84, 85, 86, 87, 88] such as trauma patients [89, 90] and patients suffering from severe burns [91, 92]. Newer devices, such as the 'bone injection gun', may increase the already widespread use of IO access [93, 94].

The IO technique is included in standard protocols and training procedures [95, 96], such as the Advanced Paediatric Life Support textbook, and it is recommended by the American Heart Association, the American Academy of Paediatrics, and the American College of Surgeons [97].

IO lines are not commonly used in newborn infants; however, it is recommended in neonates as an alternative route for medications/volume expansion if umbilical or other direct venous access is not readily available [98, 99, 100]. Neonates were included in some series of IO therapy [101], but only few studies examined this route in neonates and premature infants [99, 102]. Successful use in an 800 g baby has been reported [103]. Additionally, in a model of neonatal emergency vascular access, the IO route was found to be faster and easier than conventional umbilical venous catheterization [104].

Complications from the use of IO access occur rarely and include fractures and osteomyelitis after long-term use of IO access [105, 106] or when hypertonic solutions have been used. Fat embolism is less likely in children than in adults and has minimal clinical consequences [107]. Local extravasation of fluids due to incomplete penetration of the needle into the cortex, IO infusion into a fractured limb, or perforation of the bone may lead to a compartment syndrome [108, 109]. Finally, follow up in neonates ruled out concerns regarding injury to growing bone and the growth plate [110].

## Peripheral venous cutdown

The technique of venous cutdown is part of the training programme of Advanced Paediatric Life Support. The most preferred cutdown access site is the saphenous vein above the medial malleolus of the tibia, but antecubital, axillary, cephalic and femoral vessels are also suitable [111] and improved procedures using Seldinger techniques have been reported.

Currently, cutdown procedures are regarded as the methods of last resort. The usual time to achieve access by paediatric surgeons was 6 min in children aged 6–16 years, 8 min in those aged 1 month to 5 years, and 11 min in neonates [112]. This time delay makes its use unrealistic for most clinicians, and IO or percutaneous femoral access can be achieved more rapidly [21, 113].

## **Conclusion**

Application of local warmth proved to be beneficial in increasing the success rate of peripheral venipuncture in children, even in small patients. Transillumination techniques with the use of simple devices such as an otoscope may be a useful adjunct for rapid venous access in all infants in whom placement of an intravenous catheter is considered difficult.

Application of epidermal nitroglycerine, especially when combined with topical local anaesthetics, can be recommended in infants and children. Its use in neonates and premature babies, however, appears to be associated with higher rates of side effects.

Percutaneous central venous line insertion has replaced peripheral venous cutdown as the primary mode of short-term venous access in childhood. Venous cutdown is regarded as the method of last resort, but remains useful in emergency situations when other attempts at venous access have failed. The CVC can be inserted into the femoral, jugular and subclavian veins, or other influent veins, and in most cases catheter insertion is feasible. Published data indicate that percutaneous femoral venous cannulation is a safe and reliable technique in children of all ages, and is associated with high success and low complication rates; it should be recommended first. Percutaneous subclavian vein catheterization is commonly used in critically ill children of all ages, and is associated with relatively few serious complications in experienced hands. Cannulation of the internal jugular vein may be difficult because of anatomical variation in the vessel. Ultrasound-guided cannulation of the IJV has exhibited significant advantage over classical landmark and palpation methods, and Trendelenburg and Valsalva manoeuvres increase the diameter of the IJV significantly during cannulation. The EJV is an attractive alternative for central venous access in children and is associated with a very low complication rate. Finally, axillary vein cannulation offers an attractive alternative site for CVC insertion in the critically ill child or neonate.

The IO route provides rapid and reliable access to the systemic venous circulation in the paediatric population. This technique is safe, complications are infrequent and the benefits clearly outweigh the risks, especially in the paediatric population. Therefore, the IO technique has almost completely replaced saphenous cutdown procedures in children in emergency situations, while decreasing the need for immediate central line insertion.

## **Abbreviations**

*CVC:*

central venous catheter

*EJV:*

external jugular vein



*EMLA:*

eutectic mixture of local anaesthetics

*GTN:*

nitroglycerine

*IJV:*

internal jugular vein

*IO:*

intraosseous.

## Declarations

### Authors' original submitted files for images

Below are the links to the authors' original submitted files for images.

[13054\\_2004\\_2879\\_MOESM1\\_ESM.tiff](#) Authors' original file for figure 1

### Competing interests

None declared.

## References

1. Orłowski JP: **My kingdom for an intravenous line.** *Am J Dis Child* 1984, **138**: 803. [PubMedGoogle Scholar](#)
2. Lenhardt R, Seybold T, Kimberger O, Stoiser B, Sessler DI: **Local warming and insertion of peripheral venous cannulas: single blinded prospective randomised controlled trial and single blinded randomised crossover trial.** *BMJ* 2002, **325**: 409-410. [10.1136/bmj.325.7361.409PubMed CentralPubMedGoogle Scholar](#)
3. Wall PM, Kuhns LR: **Percutaneous arterial sampling using transillumination.** *Pediatrics* 1977, **Suppl**: 1032-1035. [Google Scholar](#)
4. Bellotti GA, Bedford RF, Arnold WP: **Fiberoptic transillumination for intravenous cannulation under general anesthesia.** *Anesth Analg* 1981, **60**: 348-351. [PubMedGoogle Scholar](#)
5. Nyamuginduru G: **Fiberoptic 'cold' light burn.** *BMJ* 1995, **310**: 1478. [Google Scholar](#)
6. Withey SJ, Moss AL, Williams GJ: **Cold light, heat burn.** *Burns* 2000, **26**: 414-415. [10.1016/S0305-4179\(99\)00145-XPubMedGoogle Scholar](#)
7. Goren A, Laufer J, Yativ N, Kuint J, Ben Ackon M, Rubinshtein M, Paret G, Augarten A: **Transillumination of the palm for venipuncture in infants.** *Pediatr Emerg Care* 2001, **17**: 130-131. [10.1097/00006565-200104000-00013PubMedGoogle Scholar](#)
8. Hecker JF, Lewis GB, Stanley H: **Nitroglycerine ointment as an aid to venepuncture.** *Lancet* 1983, **1**: 332-333. [10.1016/S0140-6736\(83\)91631-8PubMedGoogle Scholar](#)

9. Lohmann M, Moller P, Brynitz S, Bjerrum OW: **Nitroglycerin ointment as aid to venepuncture.** *Lancet* 1984, **1**: 1416-1417. [10.1016/S0140-6736\(84\)91918-4](https://doi.org/10.1016/S0140-6736(84)91918-4)[PubMedGoogle Scholar](#)
10. Khanlari B, Linder L, Haefeli WE: **Local effect of transdermal isosorbide dinitrate ointment on hand vein diameter.** *Eur J Clin Pharmacol* 2001, **57**: 701-704. [10.1007/s00228-001-0379-4](https://doi.org/10.1007/s00228-001-0379-4)[PubMedGoogle Scholar](#)
11. Roberge RJ, Kelly M, Evans TC, Hobbs E, Sayre M, Cottington E: **Facilitated intravenous access through local application of nitroglycerin ointment.** *Ann Emerg Med* 1987, **16**: 546-549.[PubMedGoogle Scholar](#)
12. Vaksmann G, Rey C, Breviere GM, Smadja D, Dupuis C: **Nitroglycerine ointment as aid to venous cannulation in children.** *J Pediatr* 1987, **111**: 89-91.[PubMedGoogle Scholar](#)
13. Lenoir P, Segers M, Ramet J: **Critical study of efficiency and toxicity of transcutaneous trinitrin in infants and children [in French].** *Pediatric* 1990, **45**: 515-517.[PubMedGoogle Scholar](#)
14. Maynard EC, Oh W: **Topical nitroglycerin ointment as an aid to insertion of peripheral venous catheters in neonates.** *J Pediatr* 1989, **114**: 474-476.[PubMedGoogle Scholar](#)
15. Teillol-Foo WL, Kassab JY: **Topical glyceryl trinitrate and eutectic mixture of local anaesthetics in children. A randomised controlled trial on choice of site and ease of venous cannulation.** *Anaesthesia* 1991, **46**: 881-884.[PubMedGoogle Scholar](#)
16. Andrew M, Barker D, Laing R: **The use of glyceryl trinitrate ointment with EMLA cream for i.v. cannulation in children undergoing routine surgery.** *Anaesth Intensive Care* 2002, **30**: 321-325.[PubMedGoogle Scholar](#)
17. Chiang VW, Baskin MN: **Uses and complications of central venous catheters inserted in a pediatric emergency department.** *Pediatr Emerg Care* 2000, **16**: 230-232. [10.1097/00006565-200008000-00003](https://doi.org/10.1097/00006565-200008000-00003)[PubMedGoogle Scholar](#)
18. Newman BM, Jewett TC Jr, Karp MP, Cooney DR: **Percutaneous central venous catheterization in children: first line choice for venous access.** *J Pediatr Surg* 1986, **21**: 685-688.[PubMedGoogle Scholar](#)
19. Stenzel JP, Green TP, Fuhrman BP, Carlson PE, Marchessault RP: **Percutaneous central venous catheterization in a pediatric intensive care unit: a survival analysis of complications.** *Crit Care Med* 1989, **17**: 984-988.[PubMedGoogle Scholar](#)
20. Johnson EM, Saltzman DA, Suh G, Dahms RA, Leonard AS: **Complications and risks of central venous catheter placement in children.** *Surgery* 1998, **124**: 911-916. [10.1067/msy.1998.91332](https://doi.org/10.1067/msy.1998.91332)[PubMedGoogle Scholar](#)
21. Kanter RK, Zimmerman JJ, Strauss RH, Stoeckel KA: **Pediatric emergency intravenous access. Evaluation of a protocol.** *Am J Dis Child* 1986, **140**: 132-134.[PubMedGoogle Scholar](#)
22. Kanter RK, Zimmerman JJ, Strauss RH, Stoeckel KA: **Central venous catheter insertion by femoral vein: safety and effectiveness for the pediatric patient.** *Pediatrics* 1986, **77**: 842-847.[PubMedGoogle Scholar](#)
23. Goh AY, Lum LC, Chan PW, Roziah M: **Percutaneous central venous catheterisation in critically ill children.** *Med J Malaysia* 1998, **53**: 413-416.[PubMedGoogle Scholar](#)
24. Chen KB: **Clinical experience of percutaneous femoral venous catheterization in critically ill preterm infants less than 1,000 grams.** *Anesthesiology* 2001, **95**: 637-639. [10.1097/00000542-200109000-00015](https://doi.org/10.1097/00000542-200109000-00015)[PubMedGoogle Scholar](#)
25. Venkataraman ST, Thompson AE, Orr RA: **Femoral vascular catheterization in critically ill infants and children.** *Clin Pediatr (Phil)* 1997, **36**: 311-319.[Google Scholar](#)

26. Swanson RS, Uhlig PN, Gross PL, McCabe CJ: **Emergency intravenous access through the femoral vein.** *Ann Emerg Med* 1984, **13**: 244-247. [PubMedGoogle Scholar](#)
27. Sheridan RL, Petras L, Lydon M: **Ultrasonic imaging as an adjunct to femoral venous catheterization in children.** *J Burn Care Rehabil* 1997, **18**: 156-158. [PubMedGoogle Scholar](#)
28. Abdulla F, Dietrich KA, Pramanik AK: **Percutaneous femoral venous catheterization in preterm neonates.** *J Pediatr* 1990, **117**: 788-791. [PubMedGoogle Scholar](#)
29. Casado-Flores J, Barja J, Martino R, Serrano A, Valdivielso A: **Complications of central venous catheterization in critically ill children.** *Pediatr Crit Care Med* 2001, **2**: 57-62. 10.1097/00130478-200101000-00012 [PubMedGoogle Scholar](#)
30. Stenzel JP, Green TP, Fuhrman BP, Carlson PE, Marchessault RP: **Percutaneous femoral venous catheterizations: a prospective study of complications.** *J Pediatr* 1989, **114**: 411-415. [PubMedGoogle Scholar](#)
31. Goldstein AM, Weber JM, Sheridan RL: **Femoral venous access is safe in burned children: an analysis of 224 catheters.** *J Pediatr* 1997, **130**: 442-446. [PubMedGoogle Scholar](#)
32. Talbott GA, Winters WD, Bratton SL, O'Rourke PP: **A prospective study of femoral catheter-related thrombosis in children.** *Arch Pediatr Adolesc Med* 1995, **149**: 288-291. [PubMedGoogle Scholar](#)
33. DeAngelis GA, McIlhenny J, Willson DF, Vittone S, Dwyer SJ III, Gibson JC, Alford BA: **Prevalence of deep venous thrombosis in the lower extremities of children in the intensive care unit.** *Pediatr Radiol* 1996, **26**: 821-824. [PubMedGoogle Scholar](#)
34. Gutierrez JA, Bagatell R, Samson MP, Theodorou AA, Berg RA: **Femoral central venous catheter-associated deep venous thrombosis in children with diabetic ketoacidosis.** *Crit Care Med* 2003, **31**: 80-83. 10.1097/00003246-200301000-00012 [PubMedGoogle Scholar](#)
35. Krafte-Jacobs B, Sivit CJ, Mejia R, Pollack MM: **Catheter-related thrombosis in critically ill children: comparison of catheters with and without heparin bonding.** *J Pediatr* 1995, **126**: 50-54. [PubMedGoogle Scholar](#)
36. Celermajer DS, Robinson JT, Taylor JF: **Vascular access in previously catheterised children and adolescents: a prospective study of 131 consecutive cases.** *Br Heart J* 1993, **70**: 554-557. [PubMed CentralPubMedGoogle Scholar](#)
37. Eichelberger MR, Rous PG, Hoelzer DJ, Garcia VF, Koop CE: **Percutaneous subclavian venous catheters in neonates and children.** *J Pediatr Surg* 1981, **Suppl 1**: 547-553. 10.1016/0022-3468(81)90003-8 [Google Scholar](#)
38. Male C, Chait P, Andrew M, Hanna K, Julian J, Mitchell L: **Central venous line-related thrombosis in children: association with central venous line location and insertion technique.** *Blood* 2003, **101**: 4273-4278. 10.1182/blood-2002-09-2731 [PubMedGoogle Scholar](#)
39. Venkataraman ST, Orr RA, Thompson AE: **Percutaneous infra-clavicular subclavian vein catheterization in critically ill infants and children.** *J Pediatr* 1988, **113**: 480-485. [PubMedGoogle Scholar](#)
40. Casado-Flores J, Valdivielso-Serna A, Perez-Jurado L, Pozo-Roman J, Monleon-Luque M, Garcia-Perez J, Ruiz-Beltran A, Garcia-Teresa MA: **Subclavian vein catheterization in critically ill children: analysis of 322 cannulations.** *Intensive Care Med* 1991, **17**: 350-354. [PubMedGoogle Scholar](#)
41. Finck C, Smith S, Jackson R, Wagner C: **Percutaneous subclavian central venous catheterization in children younger than one year of age.** *Am Surg* 2002, **68**: 401-404. [PubMedGoogle Scholar](#)

42. Citak A, Karabocuoglu M, Uysel R, Uzel N: **Central venous catheters in pediatric patients: subclavian venous approach as the first choice.** *Pediatr Int* 2002, **44**: 83-86. 10.1046/j.1442-200X.2002.01509.x [PubMedGoogle Scholar](#)
43. Iovino F, Pittiruti M, Buononato M, Lo Schiavo F: **Central venous catheterization: complications of different placements [in French].** *Ann Chir* 2001, **126**: 1001-1006. 10.1016/S0003-3944(01)00653-8 [PubMedGoogle Scholar](#)
44. Gualtieri E, Deppe SA, Sipperly ME, Thompson DR: **Subclavian venous catheterization: greater success rate for less experienced operators using ultrasound guidance.** *Crit Care Med* 1995, **23**: 692-697. 10.1097/00003246-199504000-00018 [PubMedGoogle Scholar](#)
45. Hind D, Calvert N, McWilliams R, Davidson A, Paisley S, Beverley C, Thomas S: **Ultrasonic locating devices for central venous cannulation: meta-analysis.** *BMJ* 2003, **327**: 361. 10.1136/bmj.327.7411.361 [PubMed CentralPubMedGoogle Scholar](#)
46. Simon L, Teboul A, Gwinner N, Boulay G, Cerceau-Delaporte S, Hamza J: **Central venous catheter placement in children: evaluation of electrocardiography using J-wire.** *Paediatr Anaesth* 1999, **9**: 501-504. 10.1046/j.1460-9592.1999.00422.x [PubMedGoogle Scholar](#)
47. Lukish J, Valladares E, Rodriguez C, Patel K, Bulas D, Newman KD, Eichelberger MR: **Classical positioning decreases subclavian vein cross-sectional area in children.** *J Trauma* 2002, **53**: 272-275. [PubMedGoogle Scholar](#)
48. Jung CW, Bahk JH, Kim MW, Lee KH, Ko H: **Head position for facilitating the superior vena caval placement of catheters during right subclavian approach in children.** *Crit Care Med* 2002, **30**: 297-299. 10.1097/00003246-200202000-00005 [PubMedGoogle Scholar](#)
49. Prince SR, Sullivan RL, Hackel A: **Percutaneous catheterization of the internal jugular vein in infants and children.** *Anesthesiology* 1976, **44**: 170-174. [PubMedGoogle Scholar](#)
50. Smith MF: **Internal jugular venous cannulation in children under 5 years of age.** *Can J Anaesth* 1990, **37**: S102. [PubMedGoogle Scholar](#)
51. Alderson PJ, Burrows FA, Stemp LI, Holtby HM: **Use of ultrasound to evaluate internal jugular vein anatomy and to facilitate central venous cannulation in paediatric patients.** *Br J Anaesth* 1993, **70**: 145-148. [PubMedGoogle Scholar](#)
52. Lichtenstein D, Saifi R, Augarde R, Prin S, Schmitt JM, Page B, Pipien I, Jardin F: **The Internal jugular veins are asymmetric. Usefulness of ultrasound before catheterization.** *Intensive Care Med* 2001, **27**: 301-305. 10.1007/s001340000792 [PubMedGoogle Scholar](#)
53. Nakayama S, Yamashita M, Osaka Y, Isobe T, Izumi H: **Right internal jugular vein venography in infants and children.** *Anesth Analg* 2001, **93**: 331-334. [PubMedGoogle Scholar](#)
54. Mallinson C, Bennett J, Hodgson P, Petros AJ: **Position of the internal jugular vein in children. A study of the anatomy using ultrasonography.** *Paediatr Anaesth* 1999, **9**: 111-114. 10.1046/j.1460-9592.1999.9220329.x [PubMedGoogle Scholar](#)
55. Caridi JG, Hawkins IF Jr, Wiechmann BN, Pevarski DJ, Tonkin JC: **Sonographic guidance when using the right internal jugular vein for central vein access.** *AJR Am J Roentgenol* 1998, **171**: 1259-1263. [PubMedGoogle Scholar](#)
56. Bennett J, Bromley P: **Doppler ultrasound guided vascular access needle in paediatric patients [letter].** *Paediatr Anaesth* 2001, **11**: 505. 10.1046/j.1460-9592.2001.0708a.x [PubMedGoogle Scholar](#)

57. MacIntyre PA, Samra G, Hatch DJ: **Preliminary experience with the Doppler ultrasound guided vascular access needle in paediatric patients.** *Paediatr Anaesth* 2000, **10**: 361-365. 10.1046/j.1460-9592.2000.00497.x [PubMedGoogle Scholar](#)
58. Gilbert TB, Seneff MG, Becker RB: **Facilitation of internal jugular venous cannulation using an audio-guided Doppler ultrasound vascular access device: results from a prospective, dual-center, randomized, crossover clinical study.** *Crit Care Med* 1995, **23**: 60-65. 10.1097/00003246-199501000-00012 [PubMedGoogle Scholar](#)
59. Vergheze ST, McGill WA, Patel RI, Sell JE, Midgley FM, Ruttimann UE: **Comparison of three techniques for internal jugular vein cannulation in infants.** *Paediatr Anaesth* 2000, **10**: 505-511. 10.1046/j.1460-9592.2000.00554.x [PubMedGoogle Scholar](#)
60. Etheridge SP, Berry JM, Krabill KA, Braunlin EA: **Echocardiographic-guided internal jugular venous cannulation in children with heart disease.** *Arch Pediatr Adolesc Med* 1995, **149**: 77-80. [PubMedGoogle Scholar](#)
61. Liberman L, Hordof AJ, Hsu DT, Pass RH: **Ultrasound-assisted cannulation of the right internal jugular vein during electrophysiologic studies in children.** *J Interv Card Electrophysiol* 2001, **5**: 177-179. 10.1023/A:1011433625768 [PubMedGoogle Scholar](#)
62. Vergheze ST, McGill WA, Patel RI, Sell JE, Midgley FM, Ruttimann UE: **Ultrasound-guided internal jugular venous cannulation in infants: a prospective comparison with the traditional palpation method.** *Anesthesiology* 1999, **91**: 71-77. 10.1097/00000542-199907000-00013 [PubMedGoogle Scholar](#)
63. Asheim P, Mostad U, Aadahl P: **Ultrasound-guided central venous cannulation in infants and children.** *Acta Anaesthesiol Scand* 2002, **46**: 390-392. 10.1034/j.1399-6576.2002.460410.x [PubMedGoogle Scholar](#)
64. Lobato EB, Florete OG Jr, Paige GB, Morey TE: **Cross-sectional area and intravascular pressure of the right internal jugular vein during anesthesia: effects of Trendelenburg position, positive intrathoracic pressure, and hepatic compression.** *J Clin Anesth* 1998, **10**: 1-5. 10.1016/S0952-8180(97)00189-X [PubMedGoogle Scholar](#)
65. Botero M, White SE, Younginer JG, Lobato EB: **Effects of trendelenburg position and positive intrathoracic pressure on internal jugular vein cross-sectional area in anesthetized children.** *J Clin Anesth* 2001, **13**: 90-93. 10.1016/S0952-8180(01)00220-3 [PubMedGoogle Scholar](#)
66. Haas N, Haas S: **Central venous catheter techniques in infants and children.** *Curr Opin Anaesthesiol* 2003, **16**: 291-303. 10.1097/00001503-200306000-00009 [PubMedGoogle Scholar](#)
67. Vergheze ST, Nath A, Zenger D, Patel RI, Kaplan RF, Patel KM: **The effects of the simulated Valsalva maneuver, liver compression, and/or Trendelenburg position on the cross-sectional area of the internal jugular vein in infants and young children.** *Anesth Analg* 2002, **94**: 250-254. [PubMedGoogle Scholar](#)
68. Suarez T, Baerwald JP, Kraus C: **Central venous access: the effects of approach, position, and head rotation on internal jugular vein cross-sectional area.** *Anesth Analg* 2002, **95**: 1519-1524. [PubMedGoogle Scholar](#)
69. Stephens BL, Lelli JL, Allen D, Snyder ME, Cobb LM: **Silastic catheterization of the axillary vein in neonates: an alternative to the internal jugular vein.** *J Pediatr Surg* 1993, **28**: 31-35. [PubMedGoogle Scholar](#)
70. Defawe G, Oriot D, Odent S, Senecal J: **Percutaneous catheterization of the axillary vein in the newborn infant [in French].** *Ann Pediatr (Paris)* 1984, **31**: 707-708. [Google Scholar](#)

71. Jourdan C, Convert J, Terrier A, Chiara Y, Lamy B, Charlot M, Artru F: **A prospective study of 180 percutaneous catheterizations of the axillary vein during resuscitation [in French].** *Cah Anesthesiol* 1991, **39**: 469-473.[PubMedGoogle Scholar](#)
72. Martin C, Bruder N, Papazian L, Saux P, Gouin F: **Catheter-related infections following axillary vein catheterization.** *Acta Anaesthesiol Scand* 1998, **42**: 52-56.[PubMedGoogle Scholar](#)
73. Martin C, Viviani X, Saux P, Gouin F: **Upper-extremity deep vein thrombosis after central venous catheterization via the axillary vein.** *Crit Care Med* 1999, **27**: 2626-2629. 10.1097/00003246-199912000-00004[PubMedGoogle Scholar](#)
74. Oriot D, Defawe G: **Percutaneous catheterization of the axillary vein in neonates.** *Crit Care Med* 1988, **16**: 285-286.[PubMedGoogle Scholar](#)
75. Mason DG, Weir PM: **Axillary vein cannulation in neonates [letter].** *Crit Care Med* 1991, **19**: 303.[PubMedGoogle Scholar](#)
76. Metz RI, Lucking SE, Chaten FC, Williams TM, Mickell JJ: **Percutaneous catheterization of the axillary vein in infants and children.** *Pediatrics* 1990, **85**: 531-533.[PubMedGoogle Scholar](#)
77. Galloway S, Bodenham A: **Ultrasound imaging of the axillary vein: anatomical basis for central venous access.** *Br J Anaesth* 2003, **90**: 589-595. 10.1093/bja/aeg094[PubMedGoogle Scholar](#)
78. Costa FD, de Cleve R, da Motta EV, Machado MC, Pinotti HW: **External jugular vein as central venous access in intensive care patients [in Portuguese].** *Rev Hosp Clin Fac Med Sao Paulo* 1994, **49**: 157-159.[PubMedGoogle Scholar](#)
79. Humphrey MJ, Blitt CD: **Central venous access in children via the external jugular vein.** *Anesthesiology* 1982, **57**: 50-51.[PubMedGoogle Scholar](#)
80. Nicolson SC, Sweeney MF, Moore RA, Jobs DR: **Comparison of internal and external jugular cannulation of the central circulation in the pediatric patient.** *Crit Care Med* 1985, **13**: 747-749.[PubMedGoogle Scholar](#)
81. Mitto P, Barankay A, Spath P, Kunkel R, Richter JA: **Central venous catheterization in infants and children with congenital heart diseases: experiences with 500 consecutive catheter placements.** *Pediatr Cardiol* 1992, **13**: 14-19.[PubMedGoogle Scholar](#)
82. Longo S, Cappone C, Saracco P, Bianco R, Oddenino O, Seberich C, Valori A, Miniero R: **The external left jugular vein as an access for placement of long-term permanent central venous catheters in children [in Italian].** *Minerva Pediatr* 1989, **41**: 183-187.[PubMedGoogle Scholar](#)
83. Soong WJ, Jeng MJ, Hwang B: **The evaluation of percutaneous central venous catheters: a convenient technique in pediatric patients.** *Intensive Care Med* 1995, **21**: 759-765.[PubMedGoogle Scholar](#)
84. Jaimovich DG, Kecskes S: **Intraosseous infusion: a re-discovered procedure as an alternative for pediatric vascular access.** *Indian J Pediatr* 1991, **58**: 329-334.[PubMedGoogle Scholar](#)
85. Evans RJ, Jewkes F, Owen G, McCabe M, Palmer D: **Intraosseous infusion: a technique available for intravascular administration of drugs and fluids in the child with burns.** *Burns* 1995, **21**: 552-553. 10.1016/0305-4179(95)00039-E[PubMedGoogle Scholar](#)
86. Glaeser PW, Losek JD: **Emergency intraosseous infusions in children.** *Am J Emerg Med* 1986, **4**: 34-36. 10.1016/0735-6757(86)90248-2[PubMedGoogle Scholar](#)

87. Kruse JA, Vyskocil JJ, Haupt MT: **Intraosseous infusions: a flexible option for the adult or child with delayed, difficult, or impossible conventional vascular access.** *Crit Care Med* 1994, **22**: 728-729. [PubMedGoogle Scholar](#)
88. Babl FE, Vinci RJ, Bauchner H, Mottley L: **Pediatric pre-hospital advanced life support care in an urban setting.** *Pediatr Emerg Care* 2001, **17**: 5-9. 10.1097/00006565-200102000-00002 [PubMedGoogle Scholar](#)
89. Fisher R, Prosser D: **Intraosseous access in infant resuscitation [letter].** *Arch Dis Child* 2000, **83**: 87. 10.1136/adc.83.1.87f [PubMed CentralPubMedGoogle Scholar](#)
90. Kruger C: **Intraosseous access in paediatric patients in a developing country setting [letter].** *Trop Doct* 2001, **31**: 118. [PubMedGoogle Scholar](#)
91. Velasco AL, Delgado-Paredes C, Templeton J, Steigman CK, Templeton JM Jr: **Intraosseous infusion of fluids in the initial management of hypovolemic shock in young subjects.** *J Pediatr Surg* 1991, **26**: 4-8. 10.1016/0022-3468(91)90415-P [PubMedGoogle Scholar](#)
92. Guy J, Haley K, Zuspan SJ: **Use of intraosseous infusion in the pediatric trauma patient.** *J Pediatr Surg* 1993, **28**: 158-161. [PubMedGoogle Scholar](#)
93. Glaeser PW, Hellmich TR, Szewczuga D, Losek JD, Smith DS: **Five-year experience in prehospital intraosseous infusions in children and adults.** *Ann Emerg Med* 1993, **22**: 1119-1124. [PubMedGoogle Scholar](#)
94. Lindsey J: **Ready, aim, fire! New IO device simplifies vascular access in severe cases.** *J Emerg Med Serv JEMS* 2003, **28**: 97-98. [PubMedGoogle Scholar](#)
95. Calkins MD, Fitzgerald G, Bentley TB, Burris D: **Intraosseous infusion devices: a comparison for potential use in special operations.** *J Trauma* 2000, **48**: 1068-1074. [PubMedGoogle Scholar](#)
96. Seigler RS, Tecklenburg FW, Shealy R: **Prehospital intraosseous infusion by emergency medical services personnel: a prospective study.** *Pediatrics* 1989, **84**: 173-177. [PubMedGoogle Scholar](#)
97. Mackway-Jones KME, Phillips B, Wieteska S: **Intraosseous transfusion.** In *Advanced Paediatric Life Support 3 Edition* (Edited by: Group ALS). London: BMJ Books 2001, 229-230. [Google Scholar](#)
98. Niermeyer S, Kattwinkel J, Van Reempts P, Nadkarni V, Phillips B, Zideman D, Azzopardi D, Berg R, Boyle D, Boyle R, Burchfield D, Carlo W, Chameides L, Denson S, Fallat M, Gerardi M, Gunn A, Hazinski MF, Keenan W, Knaebel S, Milner A, Perlman J, Saugstad OD, Schleien C, Solimano A, Speer M, Toce S, Wiswell T, Zaritsky A: **International Guidelines for Neonatal Resuscitation: an excerpt from the Guidelines 2000 for Cardiopulmonary Resuscitation and Emergency Cardiovascular Care: International Consensus on Science. Contributors and Reviewers for the Neonatal Resuscitation Guidelines.** *Pediatrics* 2000, **106**: E29. [PubMedGoogle Scholar](#)
99. Ellemunter H, Simma B, Trawoger R, Maurer H: **Intraosseous lines in preterm and full term neonates.** *Arch Dis Child Fetal Neonatal Ed* 1999, **80**: F74-F75. [PubMed CentralPubMedGoogle Scholar](#)
100. Lake W, Emmerson AJ: **Use of a butterfly as an intraosseous needle in an oedematous preterm infant.** *Arch Dis Child Fetal Neonatal Ed* 2003, **88**: F409. 10.1136/fn.88.5.F409 [PubMed CentralPubMedGoogle Scholar](#)
101. Moller JC, Reiss I, Schaible T: **Vascular access in neonates and infants: indications, routes, techniques and devices, complications.** *Intensive Care World* 1995, **12**: 48-53. [PubMedGoogle Scholar](#)
102. Kelsall AW: **Resuscitation with intraosseous lines in neonatal units.** *Arch Dis Child* 1993, **68**: 324-325. [PubMed CentralPubMedGoogle Scholar](#)

103. Ramet J, Clybouw C, Benatar A, Hachimi-Idrissi S, Corne L: **Successful use of an intraosseous infusion in an 800 grams preterm infant.** *Eur J Emerg Med* 1998, **5**: 327-328. [PubMedGoogle Scholar](#)
104. Abe KK, Blum GT, Yamamoto LG: **Intraosseous is faster and easier than umbilical venous catheterization in newborn emergency vascular access models.** *Am J Emerg Med* 2000, **18**: 126-129. [PubMedGoogle Scholar](#)
105. La Fleche FR, Slepian MJ, Vargas J, Milzman DP: **Iatrogenic bilateral tibial fractures after intraosseous infusion attempts in a 3-month-old infant.** *Ann Emerg Med* 1989, **18**: 1099-1101. [PubMedGoogle Scholar](#)
106. Stoll E, Golej J, Burda G, Hermon M, Boigner H, Trittenwein G: **Osteomyelitis at the injection site of adrenalin through an intraosseous needle in a 3-month-old infant.** *Resuscitation* 2002, **53**: 315-318. 10.1016/S0300-9572(02)00039-4 [PubMedGoogle Scholar](#)
107. Hasan MY, Kissoon N, Khan TM, Saldajeno V, Goldstein J, Murphy SP: **Intraosseous infusion and pulmonary fat embolism.** *Pediatr Crit Care Med* 2001, **2**: 133-138. 10.1097/00130478-200104000-00007 [PubMedGoogle Scholar](#)
108. Wright R, Reynolds SL, Nachtsheim B: **Compartment syndrome secondary to prolonged intraosseous infusion.** *Pediatr Emerg Care* 1994, **10**: 157-159. [PubMedGoogle Scholar](#)
109. Galpin RD, Kronick JB, Willis RB, Frewen TC: **Bilateral lower extremity compartment syndromes secondary to intraosseous fluid resuscitation.** *J Pediatr Orthop* 1991, **11**: 773-776. [PubMedGoogle Scholar](#)
110. Fiser RT, Walker WM, Seibert JJ, McCarthy R, Fiser DH: **Tibial length following intraosseous infusion: a prospective, radiographic analysis.** *Pediatr Emerg Care* 1997, **13**: 186-188. [PubMedGoogle Scholar](#)
111. Kissoon N, Frewen TC: **Pediatric venous cutdowns: utility in emergency situations.** *Pediatr Emerg Care* 1987, **3**: 218. [PubMedGoogle Scholar](#)
112. Iserson KV, Criss EA: **Pediatric venous cutdowns: utility in emergency situations.** *Pediatr Emerg Care* 1986, **2**: 231-234. [PubMedGoogle Scholar](#)
113. Westfall MD, Price KR, Lambert M, Himmelman R, Kacey D, Dorevitch S, Mathews J: **Intravenous access in the critically ill trauma patient: a multicentered, prospective, randomized trial of saphenous cutdown and percutaneous femoral access.** *Ann Emerg Med* 1994, **23**: 541-545. [PubMedGoogle Scholar](#)
114. Banerjee S, Singhi SC, Singh S, Singh M: **The intraosseous route is a suitable alternative to intravenous route for fluid resuscitation in severely dehydrated children.** *Indian Pediatr* 1994, **31**: 1511-1520. [PubMedGoogle Scholar](#)
115. Glaeser PW, Losek JD, Nelson DB, Bonadio WA, Smith DS, Walsh-Kelly C, Hennes H: **Pediatric intraosseous infusions: impact on vascular access time.** *Am J Emerg Med* 1988, **6**: 330-332. 10.1016/0735-6757(88)90149-0 [PubMedGoogle Scholar](#)
116. Goldstein B, Doody D, Briggs S: **Emergency intraosseous infusion in severely burned children.** *Pediatr Emerg Care* 1990, **6**: 195-197. [PubMedGoogle Scholar](#)

## Copyright