

# Spinal Anesthesia Technique

It is difficult to teach a technique by describing it. Only through experience can one obtain a “feel” for the technique. We will, however, cover some important material that will be helpful when administering spinal anesthetics.

## Technique

The technique of administering spinal anesthesia can be described as the “4 P’s”: preparation, position, projection, and puncture.

## Preparation

Preparation of equipment/medications is the first step. It is important to think ahead.

- Discuss with the patient options for anesthesia. Explain risk and benefits. Inform the patient about the following: despite sedation the patient may remember portions of the surgical procedure but shouldn’t feel discomfort, the patient may feel pressure sensations but no pain, the patient will not be able to move their legs, and the approximate length of time that the block will last.
- Choose an appropriate local anesthetic. What local anesthetic should be used? Should it be a hypobaric, hyperbaric, or isobaric preparation? The duration of blockade should match the proposed length of the surgical procedure. Consider additives at this point. The addition of epinephrine may be considered to prolong and/or improve the quality of the block.
- Choose the appropriate spinal needle. Spinal needles are available in a variety of sizes (from 16-30 gauge), lengths, bevel types, and tip designs. Commonly, a 22 gauge needle is used in patients that are 50 years and older. A 25-27 gauge needle is used in patients that are less than 50 years of age. A smaller needle is used in the younger patient to decrease the incidence of post dural puncture headache. The removable stylet occludes the lumen and avoids tracking tissue into the subarachnoid space. Needles are cutting or blunt tipped. The Quincke needle is an example of a cutting needle, with the opening at the end of the needle.



Front View



Side View

- Blunt tipped needles (pencil point) decrease the incidence of postdural puncture headaches compared to cutting needles. Whitacre and other pencil point needles, have a rounded tip with a side port. Sprotte needles have a long opening, allowing for excellent CSF flow.



Front View



Side View

This may also lead to failed blocks since the opening may be partially within the subarachnoid space, leading to a partial dose of local anesthetic being administered.

- Prepackaged spinal kits are normally used and can be custom made.

- If a prepackaged spinal kit is not available, assemble the following equipment:
  - ✓ sterile towels
  - ✓ sterile gloves
  - ✓ sterile spinal needle
  - ✓ an introducer needle if using a small gauge needle (this can be a sterile 19 gauge disposable needle)
  - ✓ sterile filter needle to draw up medications
  - ✓ sterile 5 ml syringe for the spinal solution
  - ✓ sterile 2 ml syringe with a small gauge needle to localize the skin prior initiation of the spinal anesthetic
  - ✓ antiseptics for the skin (such as betadine, chlorhexidine, methyl alcohol)
  - ✓ sterile gauze for skin cleansing and to wipe off excess antiseptic at needle puncture site
  - ✓ single use preservative free local anesthetic ampoule. Local anesthetics from multi dose vials or those that contain preservatives should NEVER be used for spinal anesthesia. Ensure that the local anesthetic preparation is made specifically for spinal anesthesia.
- Prior to initiating a spinal block, carefully wash your hands.
- The patient should be attached to standard monitors including ECG, blood pressure, and pulse oximetry. Record an initial set of vital signs.
- Preload the patient with 1-1.5 liters of crystalloid intravenous solution.
- At any point during the administration of spinal anesthesia, if sterility is questioned or contamination of equipment occurs, stop, and start over with sterile equipment.

## Positioning

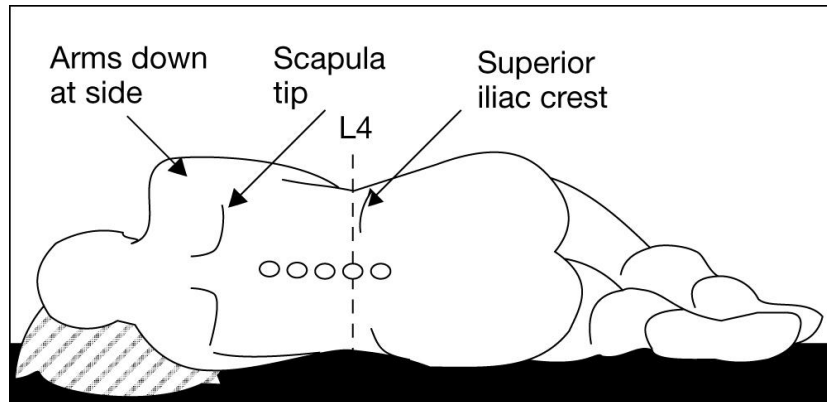
Proper positioning is essential for a successful block. Proper positioning can be difficult for several reasons.

1. Your assistant may not understand how the patient should be positioned or the rationale behind positioning.
2. The patient may not understand your instructions.
3. Sedation may make the patient unable to cooperate or follow directions.

There are three positions used for the administration of spinal anesthesia: lateral decubitus, sitting, and prone.

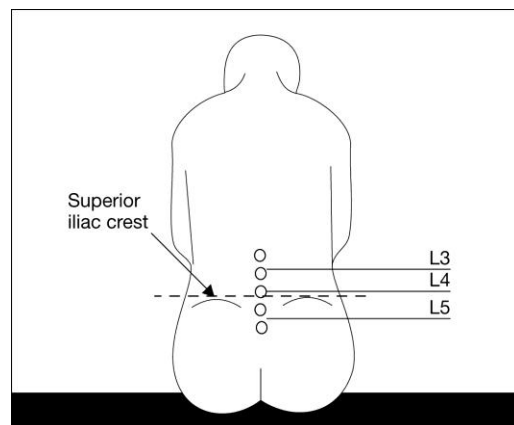
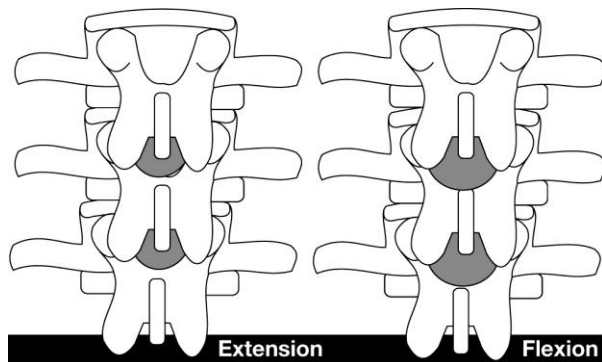
## Lateral Decubitus

- Allows the anesthesia provider to administer more sedation- less dependence on an assistant for positioning. (Never over sedate a patient).
- The patient is positioned with their back parallel with the side of the OR table. Thighs are flexed up, and neck is flexed forward (fetal position).
- Patient should be positioned to take advantage of the baricity of the spinal local anesthetic.



## Sitting

- Used for anesthesia of the lumbar and sacral levels (urological, perineal). Higher levels of anesthesia can be obtained if an appropriate dose of local anesthetic is administered, and the patient is quickly positioned to maximize the spread of local anesthetic.
- Identify anatomical landmarks. This may be a challenge in the obese or those with abnormal anatomical curvatures of the spine.
- Place the patient's feet on a stool, have the patient sit up straight, head flexed, arms hugging a pillow, or on a table in front of them. Make sure the patient does not simply lean forward. A number of descriptions may help the patient understand how they should position themselves. For example, "please arch your back to resemble the letter C; or arch your back like a mad cat". This will maximize the "opening" of the vertebral interspaces.
- For a lower lumbar/sacral block (i.e. saddle block), leave the patient sitting for 5 minutes before assuming a supine position.



## Prone

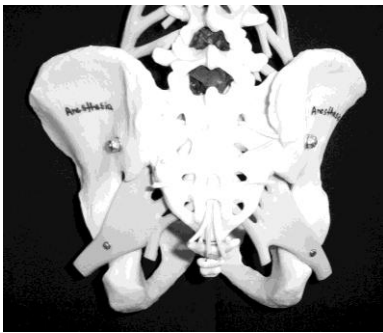
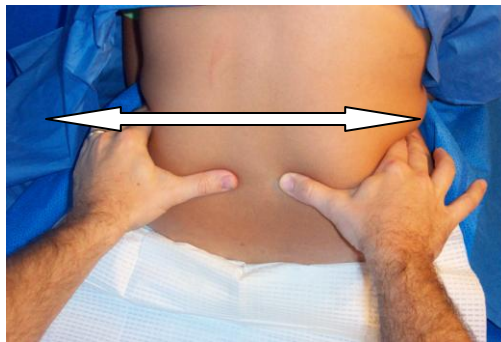
- The prone position is used when the patient will be in this position for the surgical procedure (i.e. rectal, perineal, lumbar procedures).
- Hypobaric local anesthetics are administered
- Patient positions self, lumbar lordosis should be minimized, a paramedian approach is often used.

## Projection and Puncture

There are two approaches to accessing the subarachnoid space: the paramedian and midline approach.

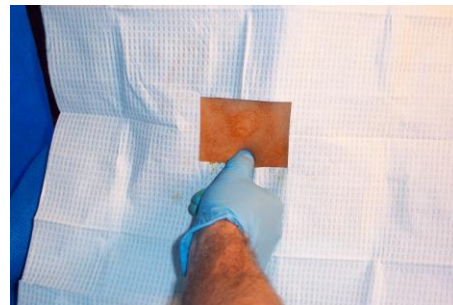
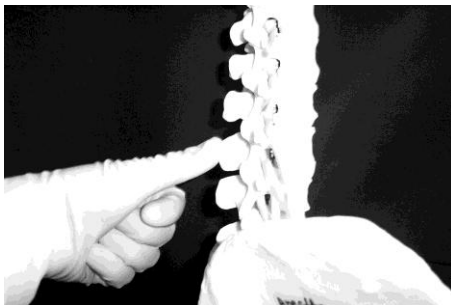### Midline Approach

The midline approach affords the practitioner two advantages. Anatomic projection is only in 2 planes, making visualization of the intended trajectory and anatomical structures more apparent. The midline provides a relatively avascular plane. It is important to have the patient sitting up straight, not slumping to the side, to minimize lumbar lordosis, and maximize the space between the spinous processes. By proper positioning you should have access to L2-L3, L3-L4, L4-L5, and L5-S1. Identify the top of the iliac crest. Tuffier's line generally corresponds with the 4<sup>th</sup> lumbar vertebrae.



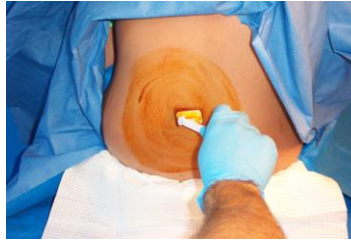**“Tuffier’s” line is a line drawn across the iliac crest that crosses the body of L4 or L4-L5 interspace. This is a helpful landmark for the placement of spinal or epidural anesthetics.**

- Palpation in the midline should help to identify the interspinous ligament. The extent of the space is noted by palpating the cephalad and caudad spine. The midline is noted by moving your fingers from medial to lateral.

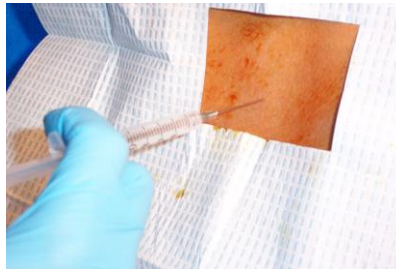

- Wash hands, put on sterile gloves, use sterile technique.

- Prepare the tray in a sterile fashion. An assistant may help with opening, in sterile fashion, specific items. Prepare the back with an antiseptic. Start at the area of intended injection and move out. This is done three times.

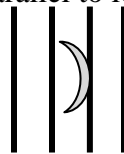


- Place a skin wheal of local anesthetic at the intended spinous interspace. Smaller gauge needles will require an introducer to stabilize the needle. Place the introducer firmly into the interspinous ligament.



- Anatomical structures that will be transversed include skin, subcutaneous fat, supraspinous ligament, interspinous ligament, ligamentum flavum, epidural space, and dura.
- Grasp the introducer with one hand and hold the spinal needle like a dart/pencil. Cutting needles should be inserted with the bevel parallel to the longitudinal fibers of the dura. This helps reduce cutting fibers and enhances tactile sensation as anatomical structures are crossed.

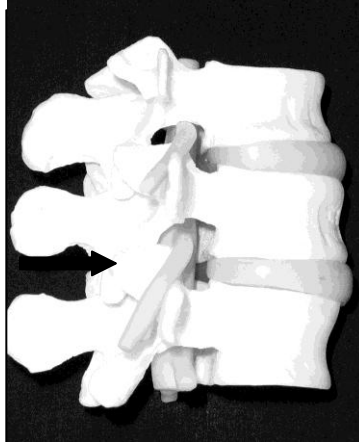
Placing needle bevel parallel to longitudinal fibers



- Control the needle carefully. Be prepared for unanticipated movement of the patient.
- As the ligamentum flavum and dura are transversed, a change in resistance is noted. Some will describe this as a “pop”; however, it may be a decrease in pressure or a loss of resistance.
- Once in the subarachnoid space, remove the stylet and CSF should appear. If CSF does not appear, rotate the needle 90 degrees until it appears. If no CSF appears then the stylet should be replaced. With smaller gauged needles it may take 20-30 seconds for CSF to appear. Assess the needle position. Is it at an appropriate depth? Is it midline or is its trajectory off the midline? Being off the midline is one of the most common reasons that CSF does not come back. If off the midline, remove the needle and start over.
- If blood returns from the needle, wait to see if it clears. If it does not clear, reassess needle position. If the needle is midline, not lateral, it may be in an epidural vein. Advance the

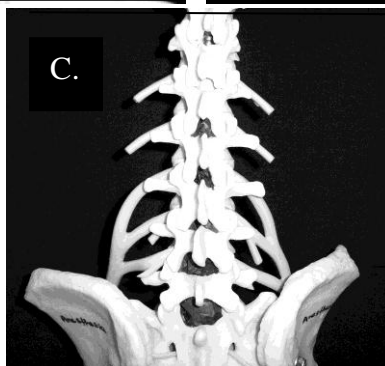
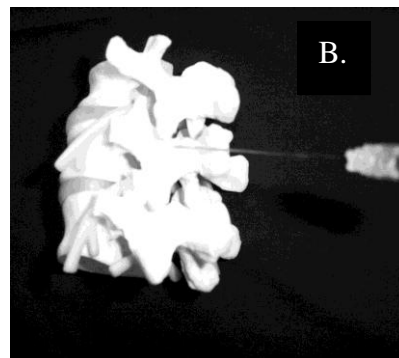
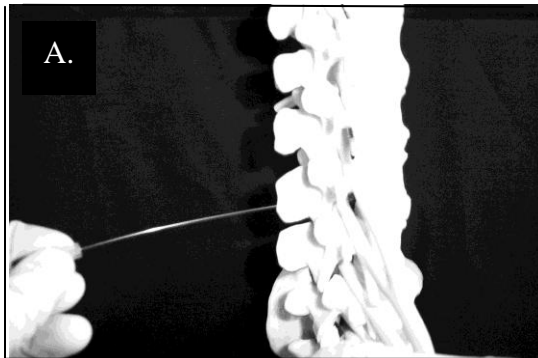
needle slightly further to transverse the dura. If the needle is not midline, remove it and start over.

- If the patient complains of a sharp pain in the hips or legs while inserting the needle, immediately remove the needle and reassess the approach. When the needle is not midline it is not uncommon to encounter a nerve root. Before starting again make sure that the pain has stopped.



**Pain/paresthesia may occur due to contact with a spinal nerve root.**

- If bone is encountered, reassess the patient's position and ensure the needle is midline. If bone is contacted early, the needle may be contacting the spinous process. Move the needle slightly caudad (A). If bone is contacted late, the needle may be contacting the lamina of the vertebrae. Move the needle slightly cephalad (B). Moving down an interspace may increase the chance of success since the intervertebral spaces will be larger (C).



- After unsuccessful attempts, consider converting to a general anesthetic. The more attempts, the more trauma, increasing the risk of a spinal/epidural hematoma.
- Once CSF returns, steady the needle with the dorsum of the non dominant hand against the patients back. Attach the syringe with the intended spinal anesthetic. Gently aspirate some CSF into the syringe. If a hyperbaric technique is being used, a “swirling” in the solution will be noted due to the dextrose content. Aspiration with an isobaric technique will yield additional CSF fluid into the syringe. The cerebral spinal fluid should be clear. If blood is returned with aspiration, replace the stylet and start over.
- Inject the local anesthetic at a rate of 0.2 ml per second. After injection aspirate 0.2 ml of CSF to confirm that the needle remains in the subarachnoid space. If the patient complains of pain during injection, stop immediately. Redirect the needle away from the side of pain and into the midline.
- Place the patient in the appropriate position for the procedure and baricity of the spinal anesthetic solution.

## Paramedian Approach

The advantage of the paramedian approach is a larger target. By placing the needle laterally, the anatomical limitation of the spinous process is avoided. The most common error when attempting this technique is being too far from the midline, which makes encountering the vertebral lamina more likely.

- Palpate the vertebral process and identify the caudad tip. Move 1 cm down and 1 cm laterally.
- Prepare the back with an antiseptic solution. Place a skin wheal of local anesthetic at the identified area of needle insertion. A longer needle is often required to infiltrate the tissue.
- Insert the introducer and/or spinal needle 10-15 degrees off the sagittal plane. At this point the most common error is inserting the needle too far cephalad, which results in encountering the lamina of the vertebral body. If bone is contacted, redirect the needle a little further caudad.
- It may be possible to feel the characteristic change in resistance or loss of resistance. With a lateral approach the needle is inserted further than with the midline approach.
- Once CSF is obtained, continue in the same manner as the midline approach.

## Monitoring

After successful placement, the patient should be monitored continuously for block progression and complications. The patient’s blood pressure should be taken every 3 minutes initially, more frequently if needed. The patient should be monitored for the following:

- Block progression- ensure that the block is adequate for the surgical procedure and it does not progress too high.
- Hypotension- treat aggressively, if blood pressure decreases by 20% or more from baseline
- Bradycardia- treat aggressively, it may progress to cardiac arrest
- Numbness of the arms and hands- may indicate that the block is too high
- Problems with breathing- may indicate that the block is too high
- Changes in the level of consciousness

An in-depth discussion of the complications of neuraxial complications have been discussed earlier.

## **Obstetric Care**

Spinal anesthesia is generally preferred over a general anesthetic in the obstetric population, as long as not contraindicated. The dose of local anesthetic is often reduced up to 1/3<sup>rd</sup> due to changes in the intra-abdominal pressure and effects of hormones which increase sensitivity.

## **Postoperative Care**

Patient's recovering from a spinal anesthetic should receive the same vigilant monitoring as the patient recovering from a general anesthetic. In addition, the patient should be assessed for block regression. The patient with a spinal is more likely to experience hypotension in the postoperative period. Treatment includes a Trendelenburg position, additional intravenous fluids, oxygen, and vasopressors as needed. Urinary retention should be assessed in patients that do not have a urinary catheter. The patient should not be discharged from the recovery area until vital signs are stable and the spinal block is regressing. The patient should remain in bed until full sensory and motor function has returned. The first time a patient is ambulated, a nurse should assist the patient to ensure full function has returned.



## References

- Ankorn, C. & Casey W.F. (1993). Spinal Anaesthesia- A Practical Guide. *Update in Anaesthesia*. Issue 3; Article 2.
- Brown, D.L. (2005). Spinal, epidural, and caudal anesthesia. In R.D. Miller *Miller's Anesthesia, 6<sup>th</sup> edition*. Philadelphia: Elsevier Churchill Livingstone.
- Burkard J, Lee Olson R., Vacchiano CA. Regional Anesthesia. In JJ Nagelhout & KL Zaglaniczny (eds) *Nurse Anesthesia 3<sup>rd</sup> edition*. Pages 977-1030.
- Casey W.F. (2000). Spinal Anaesthesia- A Practical Guide. *Update in Anaesthesia*. Issue 12; Article 8.
- Dobson M.B. (2000). Conduction Anaesthesia. In *Anaesthesia at the District Hospital*. Pages 86-102. World Health Organization.
- Kleinman, W. & Mikhail, M. (2006). Spinal, epidural, & caudal blocks. In G.E. Morgan et al *Clinical Anesthesiology, 4<sup>th</sup> edition*. New York: Lange Medical Books.
- Reese, C.A. (2007). *Clinical Techniques of Regional Anesthesia*. Park Ridge, IL: AANA Publishing.
- Warren, D.T. & Liu, S.S. (2008). Neuraxial Anesthesia. In D.E. Longnecker et al (eds) *Anesthesiology*. New York: McGraw-Hill Medical.